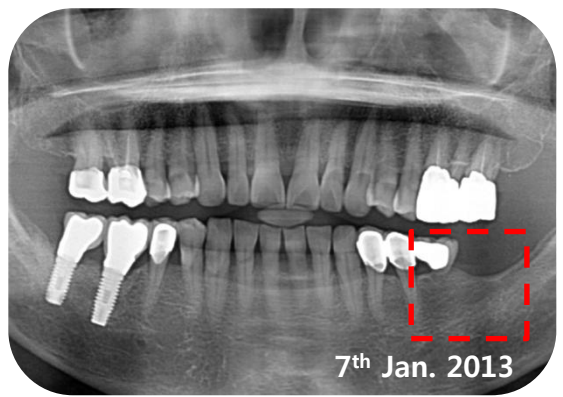


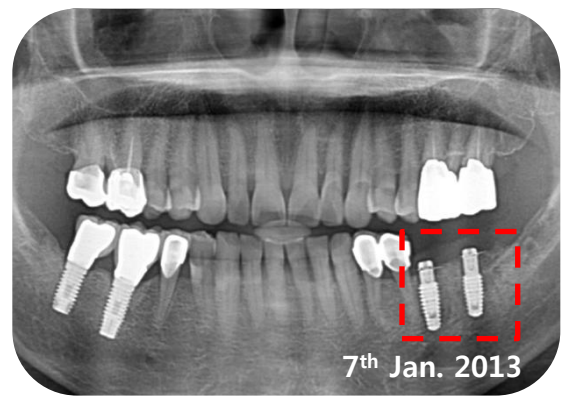
# **i-Gen<sup>TM</sup>**

**CLINICAL CASE REPORT**  
**1<sup>st</sup> Edition**

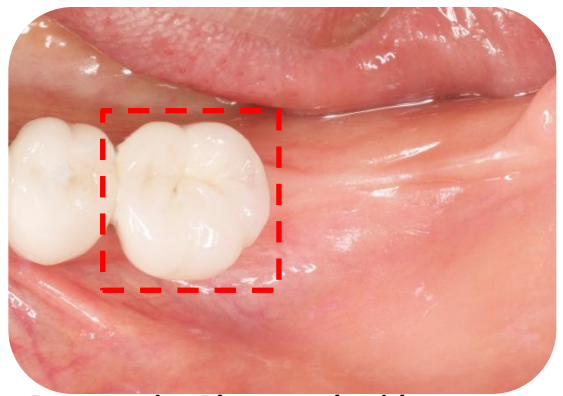
# ■ Clinical Case I . Dr. Jung Sam Lee



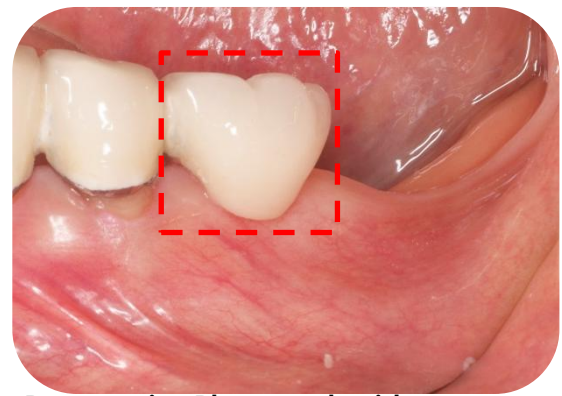
Preoperative Panoramic Radiograph



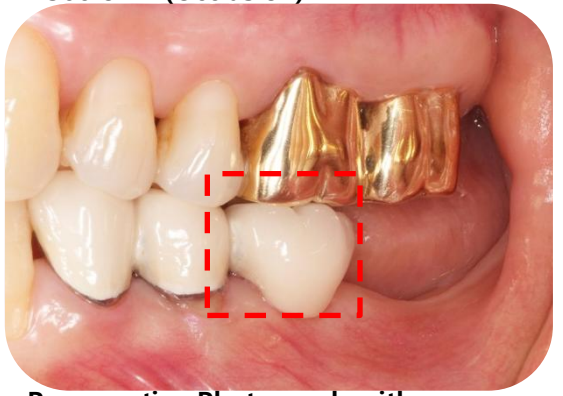
Postoperative Panoramic Radiograph



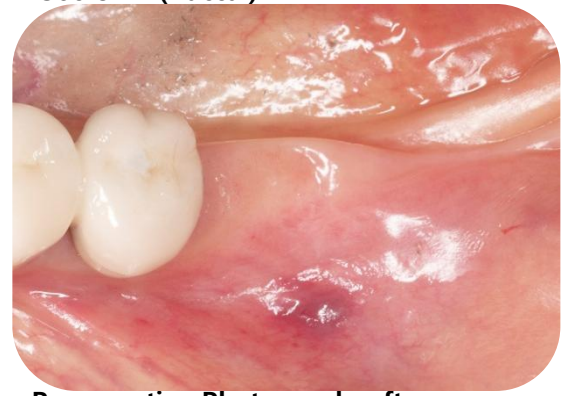Preoperative Photograph with #36crown (Occlusion)



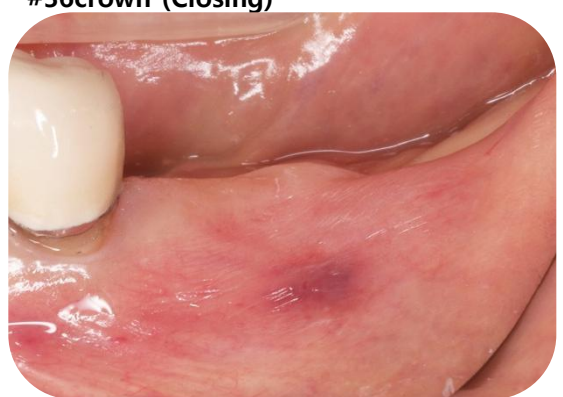Preoperative Photograph with #36crown (Buccal)



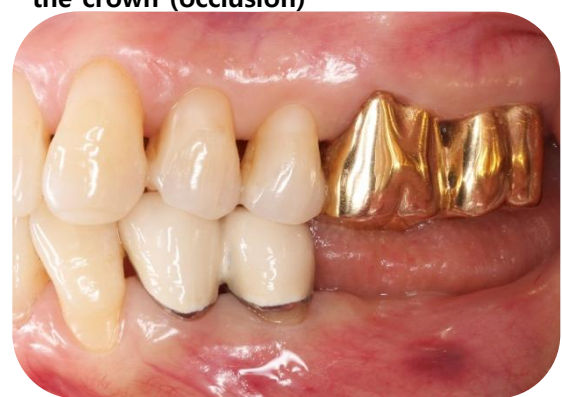Preoperative Photograph with #36crown (Closing)



Preoperative Photograph, after remove the crown (occlusion)



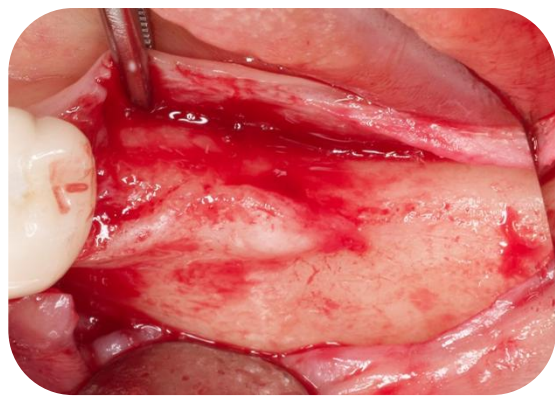
Preoperative Photograph, after remove the crown (Buccal)



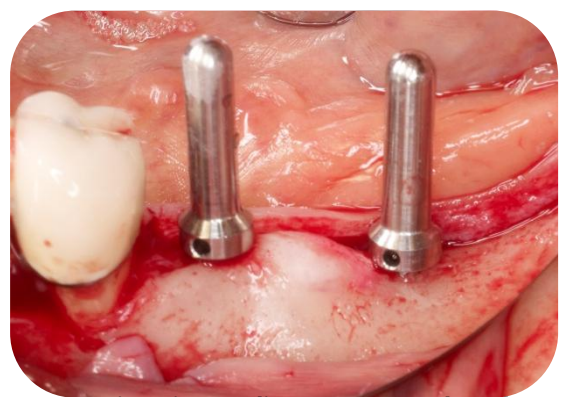
Preoperative Photograph, after remove the crown (Closing)



# ■ Clinical Case I . Dr. Jung Sam Lee



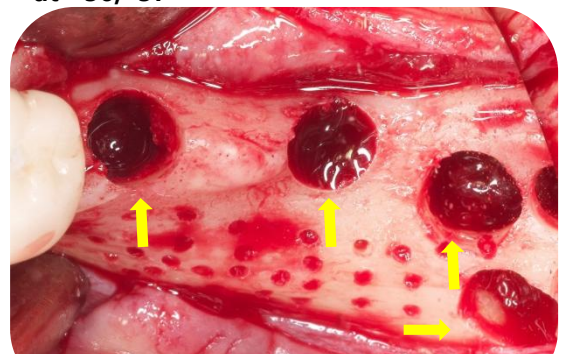
Flap reflection



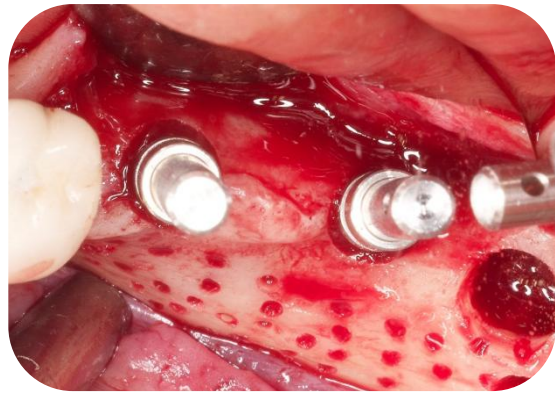
Two Direction Indicators were placed at #36,#37



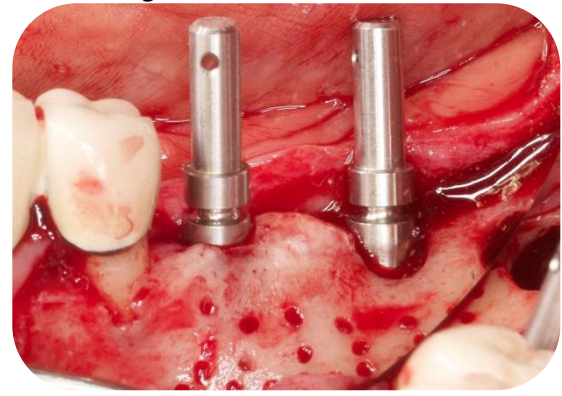
Preparing Bone Graft Material



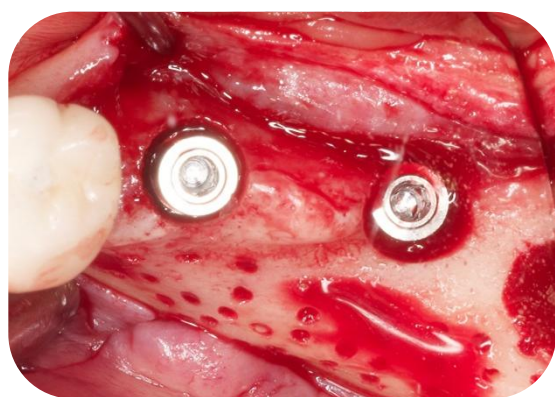
After Direction Indicating, you can see two holes of fixture path & another holes to get auto bone.



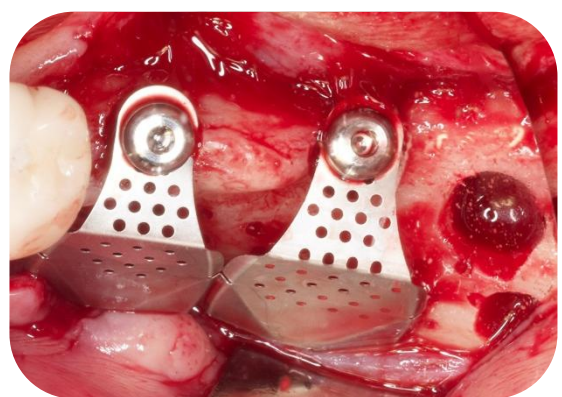
Placing Path Finders (occlusion)



Placing Path Finders (Buccal)

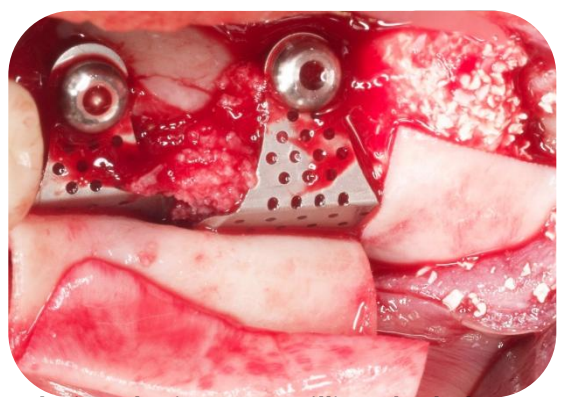


Two fixtures were placed at #36, #37

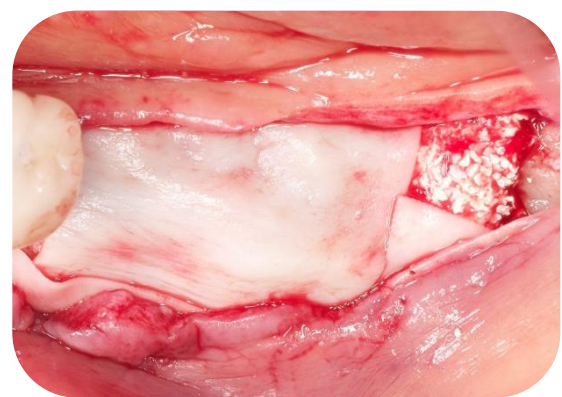


Two i-Gens were positioned and fixed with Flat Abutments.

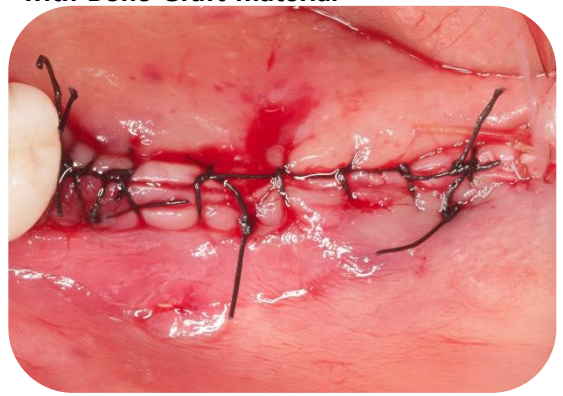# ■ Clinical Case I . Dr. Jung Sam Lee



Placing the i-Gens & Filling the holes with Bone Graft material



Covering the membrane



Suture the flap